

INDIRECT POST-IMPLANT LESIONS OF THE INFERIOR ALVEOLAR NERVE. RADIOLOGICAL AND BIOMECHANICAL FINDINGS

P. DIOTALLEVI*, E. MOGLIONI*, E. PEZZUTI**, L. BOFFA***, G. FERRANTE*, M. PASQUALINI*, P. FLORIS*

* AISI Accademia Italiana di Stomatologia Implantoprotesica (Italian Academy of Implant Prosthetic Stomatology)

** Faculty of Engineering, University of Rome "Tor Vergata", Italy

*** Chair in Neurology, University of Rome "Tor Vergata", Italy

SUMMARY

Indirect post-implant lesions of the inferior alveolar nerve. Radiological and biomechanical findings

The aim of the work. The mandibular canal, if it is affected by different illnesses, often shows typical radiological changes, made up of widespread hypodensity, an increase in its diameter and disappearing walls. This study aims to verify the reliability of such radiological signs in the cases of later post-operative lesions of the mandibular canal.

Materials and method. The study includes 16 patients, 9 males and 7 females, with an average age of 54 years, who underwent an operation to rehabilitate the mandible with a prosthetic implant for a total of 37 implants. All the subjects underwent an Orthopantomograph due to the appearance of painful radicular symptoms some time after the operation.

Results. In 36 cases out of 37 we found, with the Orthopantomograph, a slight increase in the calibre of the mandibular canal compared to the controlateral. In 10 subjects we observed hypodensity of the canal itself, while in 6 subjects the canal passages were no longer recognisable.

Conclusion. The radiological indications of damage of the inferior alveolar nerve (IAN) are reliable even in the case of indirect post-implant lesions.

Key words: inferior alveolar nerve, IAN, implant radiology.

RIASSUNTO

Lesioni post-implantari indirette del nervo alveolare inferiore. Aspetti radiologici e biomeccanici

Scopo del lavoro. Il canale mandibolare, se coinvolto da processi morbosi, mostra frequentemente tipiche alterazioni radiologiche, costituite da ipodensità diffusa, incremento del diametro e scomparsa delle pareti. Questo studio si propone di verificare l'attendibilità di tali segni radiologici nei casi di lesioni post-implantari a distanza del canale mandibolare.

Materiali e metodi. Lo studio comprende 16 pazienti, 9 uomini e 7 donne, età media 54 anni, sottoposti a intervento di riabilitazione implantoprotesica della mandibola per complessivi 37 impianti. Tutti i soggetti sono stati sottoposti a Ortopantomografia per la comparsa di sintomatologia dolorosa radicolare a distanza di tempo dall'intervento.

Risultati. In 36 casi su 37 si è riscontrato all'Ortopantomografia un lieve incremento del calibre del canale mandibolare rispetto al controlaterale. In 10 soggetti si è osservata ipodensità del canale stesso, mentre in 6 soggetti le pareti canalari sono risultate non più riconoscibili.

Conclusioni. In conclusione i segni radiologici di compromissione del nervo alveolare inferiore riscontrabili all'OPT risultano affidabili anche in caso di lesioni post-implantari indirette.

Parole chiave: nervo alveolare inferiore, IAN, radiologia implantologica.



Introduction

When the lower alveolar nerve is affected by any mechanical, iatrogenic, neoplastic or inflamma-

tory process, we can clinically see the appearance of typical trigeminal symptoms, together with typical radiological changes of the mandibular canal, consisting in widespread hypodensity, increase in diameter and disappear-

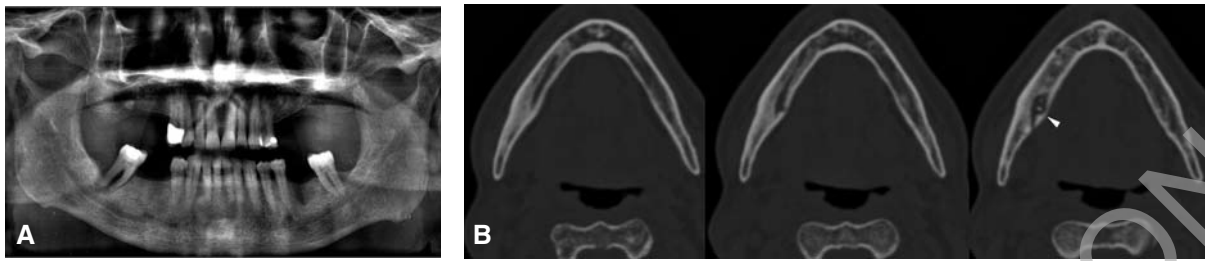


Figure 1

When the mandibular canal is affected by any illness, typical radiological changes appear which are widespread hypodensity, increase in its diameter and disappearance of the thin radio-opaque wall stria. The changes are clearly visible both from the OPT (A) and the CT scan images (B).

ance of the thin radio-opaque stria which makes up the walls (Fig. 1). The MRI and the study of trigeminal sensory evoked potentials (SEP) suggest the probable pathogenic mechanism of the clinico-radiological symptoms described, represented initially by a painful vascular-nervous band with oedema, a phase in which the symptoms appear. Subsequently, such a swelling probably exercises pressure on the bony walls of the canal, causing the appearance of typical radiological changes after about two weeks. An X ray can therefore help confirm clinical suspicions (1-5).

This study aims to check the reliability of the radiological signs in the later appearing post-implant lesions of the mandibular canal, in a group of patients with these symptoms.

Materials and methods

The study involves 16 patients, 9 males and 7 females with an average age of 54, who underwent an operation to rehabilitate the mandible with a prosthetic implant for a total of 37 implants. None of them had complained of complications in both the immediate intra or postoperative phases, since in the operations carried out the implants had neither crossed nor torn the nerve, even if they had been positioned with their tips close to the mandibular canal.

In 15 subjects the trigeminal symptoms appeared in a period of time comprising between one and

ten days after restarting mastication and, in one case, after 21 months.

One or more Orthopantomographs were carried out at the request of the dentist, soon after the functional loading of the prostheses, following the appearance of pain, paraesthesias or numbness in the area of the third branch of the trigeminal nerve. A CT scan with panoramic and cross reconstructions was carried out on 4 patients.

For each individual patient, clinical symptoms and x-rays were correlated to biomechanical analysis, through FEMS extrapolated of the images available, developed with the aim of evaluating implant response to immediate loading.

Results

In 36 patients out of 37 the OPT showed a slight increase in the calibre of the mandibular canal compared to the controlateral, with values higher than 2,5 mm. In ten subjects, (60% of cases), we observed hypodensity of the canal itself, while in six cases (37%) the canal walls were no longer recognisable (Figs. 2, 3).

Biomechanical analyses confirmed what we already knew and that is that, in addition to the pericervical transmission zone, there is also a secondary stress zone which extends around the tip of the prosthesis (Fig. 4), characterised by a radius of about 1.5-2 mm and low tensional values, comprised between 0.3 and 1 MPa.

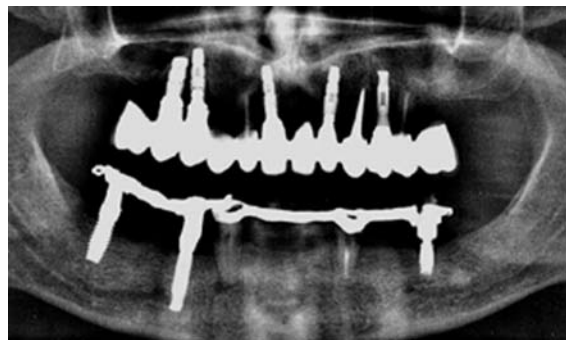


Figure 2

A 67 year old male with symptoms. The implant is positioned very close to the right chin-cap foramen. The canal appears hypodense, the bony walls are still recognisable.

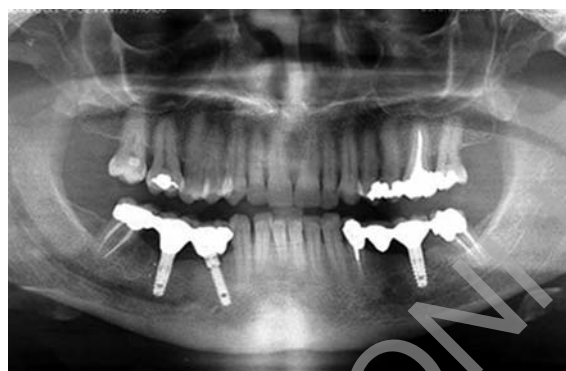

Figure 3

A 59 year old female with symptoms. In the right lower molar area, the tip of the implant is positioned near the mandibular canal, which is hypodense and slightly wider compared to the contralateral side. The walls are hardly recognisable.

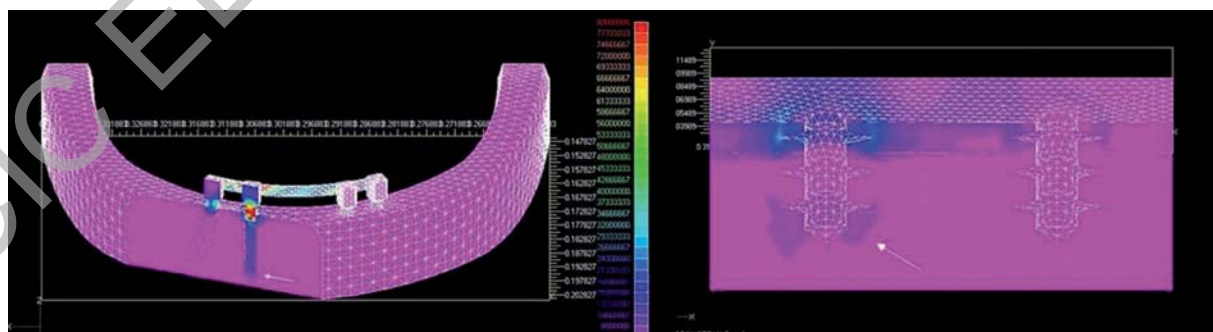


Figure 4

The biomechanical analyses show that, as well as the known area of pericervical transmission, there also exists a secondary stress area, which extends around the tip of the implant (white arrow), characterised by a radius of about 1.5 – 2 mm and low tensional values, comprised between 0.3 and 1 MPa.

The models carried out on the cases characterised by the peri-cervical resorption cone clearly show that the extension of the stress zone around the tip increases with the deepening of the cone itself, particularly when the cone goes beyond the first coil which is fixed inside the bone (Fig. 5).

Discussion

Our results indicate the generalised radiological signs indicating problems with the lower alveolar nerve are also present in the indirect post-implant lesions.

In particular, already two weeks after the functional loading of the implant, we almost always noted a widening of the mandibular canal, whose normal diameter is not bigger than 2,5 mm (1). In any case it is important to integrate the measurements with a subjective evaluation by the radiologist by comparing it to the contralateral canal.

The frequency of other symptoms found in various combinations such as canal hypodensity and disappearance of the walls is also significant (Fig. 3). In the only case in which the canal was not wider, only the disappearance of the walls was found.

Even though our study did not include the study of the reversibility of the described radiological finds, we do point out that in the 6 cases in which it was possible to carry out a check-up 6-12

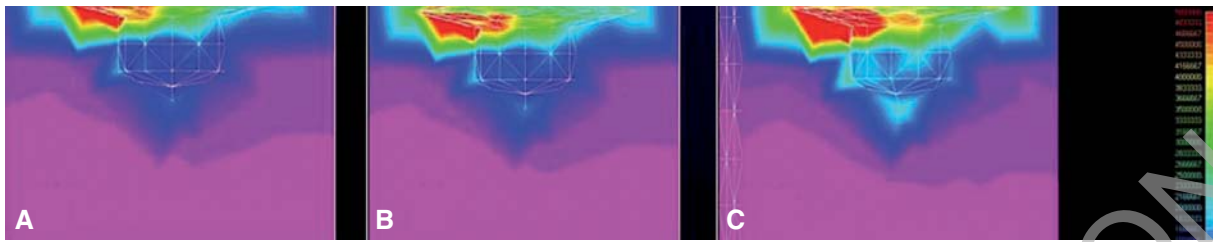


Figure 5

The FEMs show a progressive increase in the tensional values and in the extension of the stress around the tip which is proportional to the deepening of the resorption cone at the level of the implant collar. The pictures refer to the implant tip. A) Absence of pericervical resorption B) 1.5 mm resorption C) 2.5 mm resorption.

months after the disappearance of the symptoms, the radiological signs were still evident.

The secondary stress zone, which extends around the tip of the implant, effectively presents states of tension which are insufficient to cause direct lesions on the bony walls of the canal, but it is able to irritate the nerve with time and to subsequently cause, indirectly, the radiological changes that follow the symptom after a few days. The above can occur particularly if the tip is located less than 1.5 mm from the lower canal which distance corresponds to the average radius of the secondary transmission area and which could therefore be considered a safety distance.

Moreover, it is important to underline that the models carried out on cases having a pericervical resorption cone show that **the extension of the stress zone around the tip increases with the deepening of the cone itself** (Fig. 5), particularly when the cone goes beyond the first coil which is fixed inside the bone, a phenomenon that is already known (1, 6, 7). This detail probably explains one of our cases, in which the symptoms and the radiological changes only appeared after 21 months, at the same time as the deepening of the resorption cone (Fig. 6).

In conclusion, the Orthopantograph evidence of damage to the mandibular canal are also reliable in the cases of later appearing post implant lesions and are well correlated to the clinical symptom. Their appearance can be an important tool for the implantologist because they help to confirm the clinical suspicion that the lower alveolar nerve is indirectly involved.

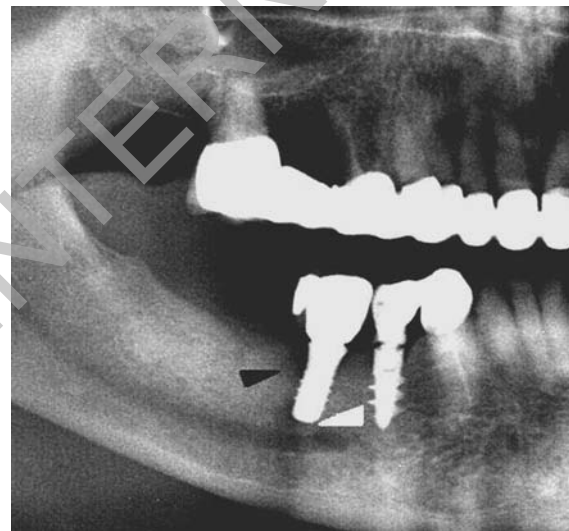


Figure 6

49 year old male. The orthopantomogram X Ray, carried out 21 months after the operation due to trigeminal pain, shows some pericervical resorption (dark arrow) and, at the same time, typical changes of the mandibular canal (white arrow). The same examination, carried out 18 months earlier did not show any lesions, either at the collar level or at the tip.



References

1. Diotallevi P, Moglioni E, Pezzuti E, Rastelli E, Floris PL Alterazioni radiologiche del canale mandibolare e aspetti biomeccanici correlati. Boll. S.M.O. 2006, 26: 2-6.

2. Gahleitner A, Solar P, Nasel C et al. Magnetic resonance tomography in dental radiology Radiologe. 1999 Dec; 39 (12): 1044-50.
3. Nasel C, Gahleitner A, Breitsenseher M. Dental MR tomography of the mandible. J Computed Assist Tomogr 1998; 22 (3): 498-502.
4. Smith AC, Barry SE, Chiong AY, Hadzakis D, Kha SL, Mok SC, Sable DL. Inferior alveolar nerve damage following removal of mandibular third molar teeth. A prospective study using panoramic radiography Aust Dent J 1997 Jun; 42 (3): 149-52.
5. Erickson M, Caruso JM, Leggitt L. Newtom QR-DVT 9000 imaging used to confirm a clinical diagnosis of iatrogenic mandibular nerve paresthesia J Calif Dent Assoc 2003; 31: 843-5.
6. Diotallevi P, Moglioni E, Pezzuti E, Pierazzini A, Pasqualini M, Floris PL. Biomechanical and radiological correlation on the resorption of the alveolar bone. A comparative study on 47 subjects. Doctor Os 2007; Feb 18 (2).
7. Diotallevi P, Moglioni E, Pezzuti E, Pierazzini A, Pasqualini M, Floris P. Współzależności biomechaniczno-radiologiczne w przypadku resorpcji okotowszczepowej tkanki kostnej. Magazyn Stomatologiczny 2008; 2: 20-26.

Correspondence to:

Dott. Paolo Diotallevi
Via Ernesto Basile, 16

00128 Rome

Tel/Fax 06-299391

E-mail: direzione@eosmed.it